

Forgotten Foreign Body in a Pregnant Woman

Aarthi K Jayraj¹ and Nanthini Saravanan^{2*}

Department of Obstetrics and Gynaecology, Jawaharlal Institute of Postgraduate Medical Education and Research (JIPMER), India

Received Date: August 11, 2023; Accepted Date: August 22, 2023; Published Date: August 24, 2023

***Corresponding author:** Nanthini Saravanan, Department of Obstetrics and Gynaecology, Jawaharlal Institute of Postgraduate Medical Education and Research (JIPMER), Karaikal, Puducherry, India

Citation: Aarthi K Jayraj and Nanthini Saravanan. Forgotten Foreign Body in a Pregnant Woman. ICARE. 2023;2(3):1043.

Copyright © 2023 Nanthini Saravanan. This is an open access article published under the Creative Commons Attribution License, which permits unrestricted use, distribution, and reproduction in any medium, provided the original work is properly cited.

Clinical Image

A 25-year-old primigravida at 33 weeks of gestation was admitted in June 2022 following blunt trauma. On examination, *vital* signs were stable, per abdominal examination had no clinical evidence of abruption which was confirmed with ultrasound. The patient had complaints of intermittent offensive white discharge for the last 11 years and dyspareunia after marriage, but she didn't seek medical care.

On per speculum and per vaginal examination, copious vaginal secretion with strange objects was felt in the upper vagina.

Evaluation under anaesthesia revealed a foreign body buried under fibrous tissue which was excised (Figure A, B) and a sharpener retrieved (Figure C, D). Steroids, tocolytics and broad-spectrum antibiotics were administered. The postoperative period was uneventful. The pregnancy progressed to term resulting in spontaneous vaginal delivery. A foreign body in the vagina is rarely considered in the differential diagnosis of vaginal discharge in a pregnant woman. Reliable history with thorough examination aids in accurate diagnosis.

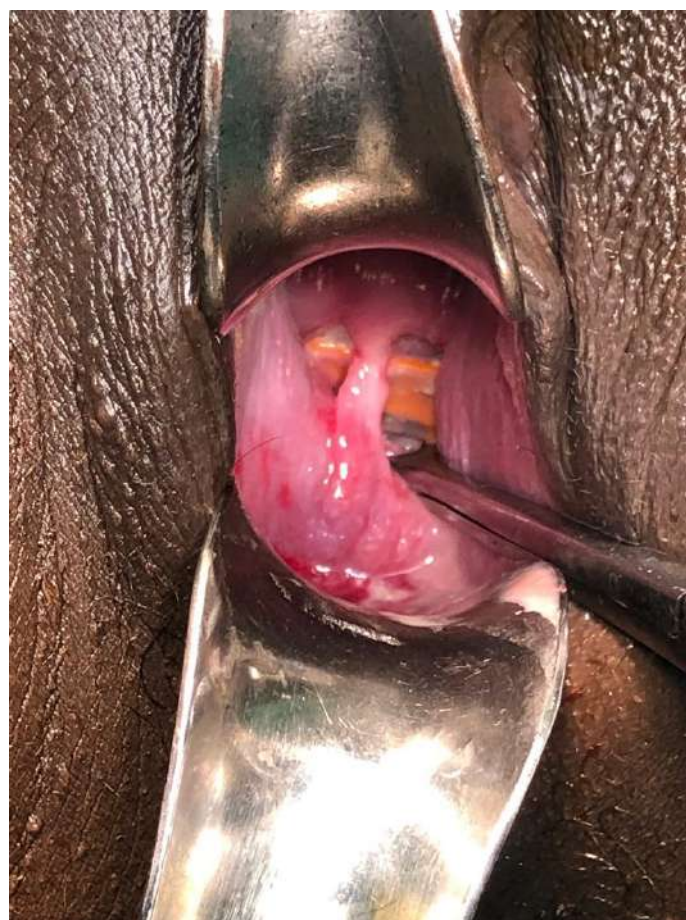

Figure A: Foreign body buried under fibrous tissue.

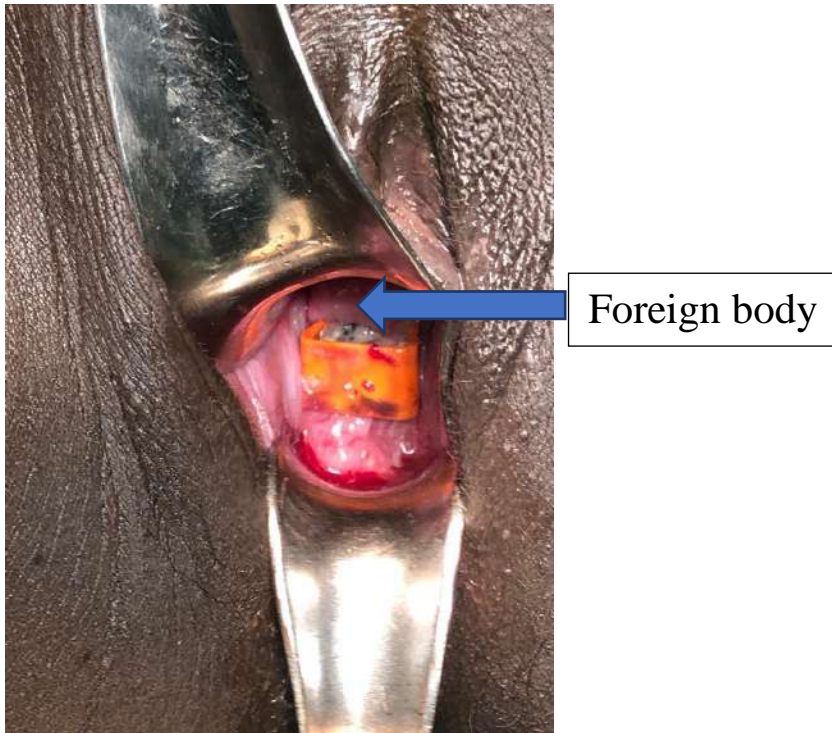


Figure B: Foreign body/sharpener revealed after fibrous tissue excision.

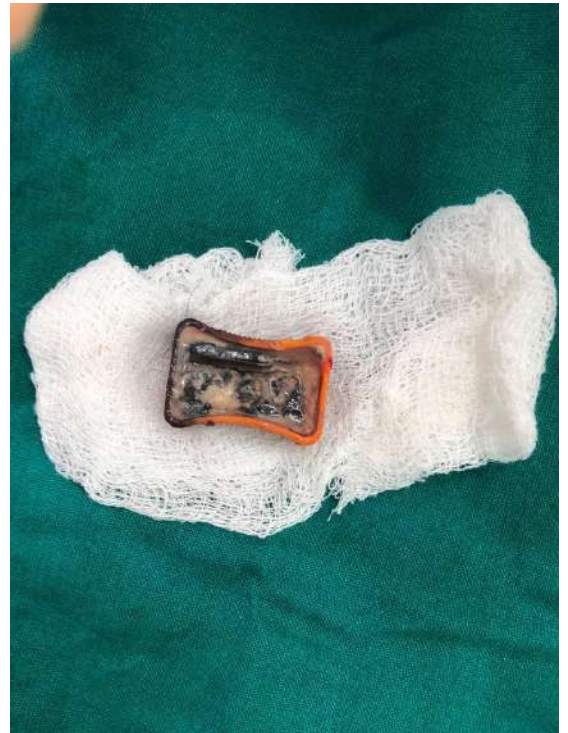

Figure D: Sharpener coated with foul-smelling vaginal discharge.

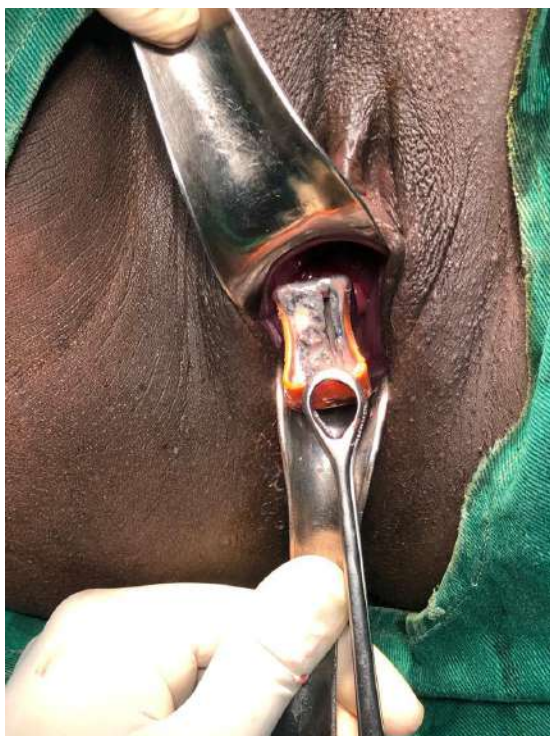


Figure C: Retrieval of Sharpener.

Contact Author:

Nanthini Saravanan, Department of Obstetrics and Gynaecology, Jawaharlal Institute of Postgraduate Medical Education and Research (JIPMER), Karaikal, Puducherry, India E-mail: drnanthini[at]gmail[dot]com