

Bilateral Axillary Lipoma an Unusual Entity

Ved Bhushan ST*, Kle U and Kaulgud AS

Consultant Surgeon, India

Received Date: April 27, 2023; Accepted Date: May 14, 2023; Published Date: May 23, 2023

***Corresponding author:** Ved Bhushan ST, Consultant Surgeon, F1 Vigna Rajendra Appartment, Klecch Yallur Road, IInd Main, 7th Cross, Sadashiv Nagar, Belagavi, 590001, India, Karnataka, E-mail: theobhushan@gmail.com

Citation: Ved Bhushan ST, Kle U and Kaulgud AS. Bilateral Axillary Lipoma Anunusual Entity. ICARE. 2023;2(3):1033.

Copyright © 2023 Ved Bhushan ST. This is an open access article published under the Creative Commons Attribution License, which permits unrestricted use, distribution, and reproduction in any medium, provided the original work is properly cited.

Abstract

Subcutaneous lipomas are very common clinical conditions. Lipomas are seen commonly over the trunk, limbs, neck, arms and legs.

Keywords: Lipoma; Axillary mass; Accessory breast

Introduction

Lipomas are common benign, soft tissue mesenchymal tumours of the adult fat cells. Lipomas are frequently seen over the trunk, legs, thighs, nape of the neck. Lipomas are small discrete swelling and are usually asymptomatic, with an estimated incidence around 10% [1].

We are presenting a case of bilateral axillary lipomas in a middle aged lady and its management.

Case Report

Mrs. D a 45 years old married lady presented to surgical OPD with the history of bilateral swellings in the axilla over 5 years. They were small initially and slowly increased in size and the patient had difficulty in wearing dresses. There was no pain but only discomfort in the arms while doing house hold work. The patient did not have hypertension or diabetes and was not on any medication.

OB/GYN history was normal.

On examination the patient was a middle aged lady in good condition with normal *vital* signs. Local examination revealed bilateral axillary swelling.

Right side swelling was larger around 8 cm × 5 cm; it was oval, soft, mobile, non- tender. Left axillary swelling was smaller a size was around 4 cm × 5 cm oval, soft, non-tender and mobile. Both the breasts were normal and there was no axillary limp node palpable. Systemic examination of CVS, RS and GIT were normal.

A clinical diagnosis of Bilateral Axillary Lipoma was made and managed after investigations.

Investigations

03/11/2022: HB-13.5 GM%, RBC-4.50, WBC-8600.O, PLATLET-271000 CELLS/CM

HBsAG - NEGATIVE,

HIV- NON REACTIVE

BT - 2.00, CT - 4.00, GLICOUSE - 85.9 mg/dl, UREA - 28.3 mg/dl, CREATININE - 1.00 mg/dl

URINE TEST, ALBUMIN-TRACE, SPECIFIC GRAVITY- 1.020, P^H-6.0,

GLUCOSE-ABSENT,

KETONE BODIES-ABSENT,

PUS CLLS-5-8,

RBC-NIL,

EPITHELIAL CELLS-NIL

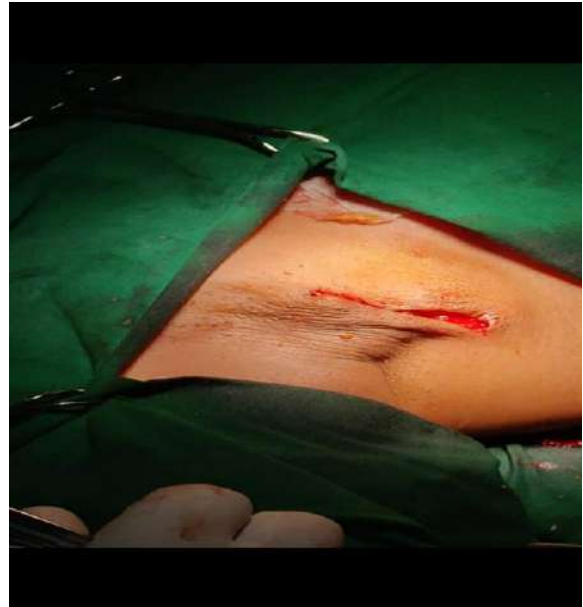
CHEST X-RAY PA VIEW-NAD, ECG-SINUS RHYTHM.

USG right axilla swelling there is an ill defined isochoric lesion with intervening hyper echoic streaks noted in subcutaneous plane, size approximately 8 cm × 4 cm × 2 cm. Few small reactive lymph noted.

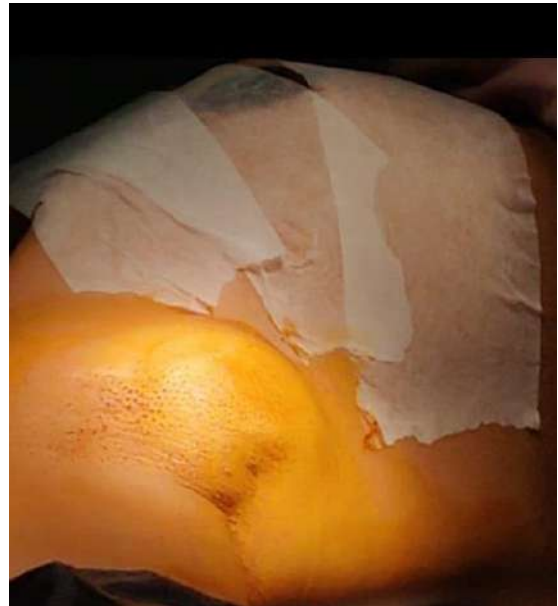USG left axilla shows swelling there is an ill defined isochoric lesion with intervening hyper echoic streaks noted in subcutaneous plane, size approximately 4 cm × 2 cm × 2 cm.

Operation Notes

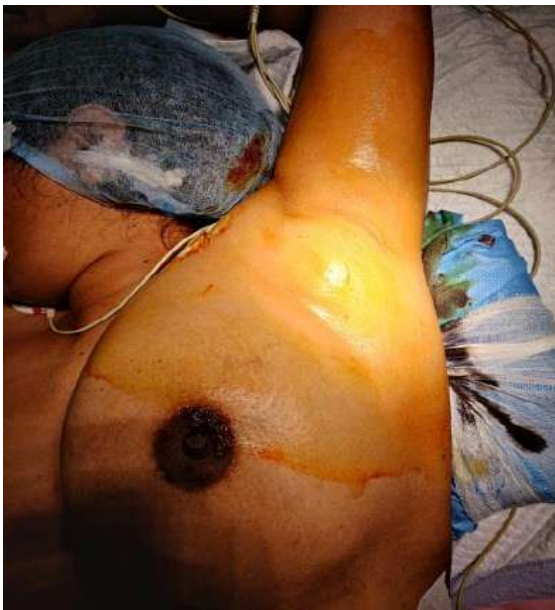The patient underwent bilateral axillary mass excision under general anaesthesia. First the right side was operated. The mass was 8 cm × 4 cm × 2 cm which was excised completely. Surgical incision was closed without drain. Similar procedure was performed on the left side; the mass was around 4 cm × 2 cm × 1½ cm (Figure 1).



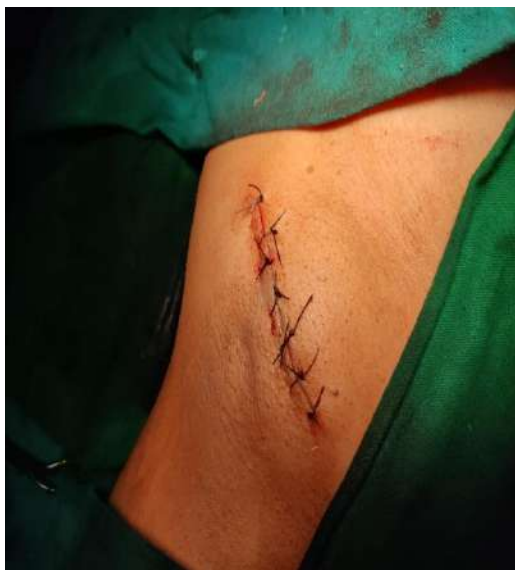1(B)



1(C)



1(A)



1(D)

Figure 1: 1A - Left side PRE-OP; 1B - Left side POST-OP; 1C - Right PRE-OP; 1D - Right POST-OP.

Discussion

Lipoma is cluster of adult fat cells which become overactive and distends with fat tissue and becomes a swelling. Lipomas are common subcutaneous swelling. It may occur in any part of the body hence it is known as UNIVERSAL TUMOUR; except in brain and palms and soles of the feet.

Lipomas can be classified as subcutaneous, sub facial, paraosteal, intramuscular, sub-serous and sub dermal.

Lipomas can be of different varieties such as encapsulated, diffuse and multiple lipomas. Lipomas may occur at any age but commonly seen in the older children and adults. Lipoma is usually single, soft, and mobile with slip sign positive.

Complications of lipoma are myxomatous degeneration, saponification, calcification, infection with ulceration and rarely LIPO SARCOMA [2]. Lipomas are subcutaneous

swelling with an average diameter of 2 cm and seldom grow to a large size [3]. Lipomas can occur over the trunk and extremities and back more commonly [4]. Large intestinal lipomas can occur which can cause pain due to pressure and may undergo sarcomata's changes [5]. Giant axillary lipoma recurrence following excision was reported in 2013 by Bashir M [6]. Bilateral giant axillary lipoma excision was reported by Dr. Aishwarya in 2021 [7]. We have successfully managed a case of bilateral axillary lipoma in a middle aged lady with excision. Pathology report has confirmed it as lipoma. Bilateral axillary lipoma is infrequent and this is only a second case reported to the best of our knowledge.

References

1. Meson H. Lipoma in clinical dermatology. Clin Dermatol. 1991;4:1-2.
2. In: Das S, editor. Manual of clinical surgery. 10th ed. Kolkata: 2014. p. 47-9.
3. Salcatore C, Antonio B, Del Vecchio W, Lanza A, Tartaro G, Giuseppe C. Giant infiltrating lipoma of the face: CT and MR imaging findings. AJNR Am J Neuroradiol. 2003;24(2):283-6.
4. Aydogdu E, Yyldyrym S, Eker G, Akoz T. Giant lipoma of the back. Dermatol Surg. 2004;30(1):121-2.
5. Enzinger FM, Weiss WS. Soft Tissue Tumors. St Louis: CV Mosby; 1988. p. 301-45.
6. Bashir M, Zaki IA, Mahajan MK. Giant Axillary Lipoma Following Excision. Indian J Surg. 2013;75 (Suppl 1):158-9.
7. Aishwarya C, Shetty R. IOSR-JDMS. 2021;20(1):55-7.