

Adult Stem Cell Therapy as an Alternative to Total Hip Arthroplasty in Severe Hip Osteoarthritis

David Ikudayisi* and Oluwatobi Oluwasanmi

Glory Wellness & Regenerative Centre, Nigeria

Received Date: March 01, 2023 Accepted Date: March 24, 2023 Published Date: April 3, 2023

***Corresponding author:** David Ikudayisi, Glory Wellness & Regenerative Centre, Block 78 Plot 14B, Dan Ogbeide Close, Lekki Phase 1, Lekki, Lagos, Nigeria, Tel: 011234-8183816733; E-mail: dayisi@aol.com

Citation: David Ikudayisi and Oluwatobi Oluwasanmi. Adult Stem Cell Therapy as an Alternative to Total Hip Arthroplasty in Severe Hip Osteoarthritis. ICARE. 2023;2(2):1026.

Copyright © 2023 David Ikudayisi. This is an open access article published under the Creative Commons Attribution License, which permits unrestricted use, distribution, and reproduction in any medium, provided the original work is properly cited.

Abstract

Objective: Hip osteoarthritis is one of the leading causes of chronic hip joint pain and disability worldwide. According to the arthritis research and therapy, the global incidence of hip osteoarthritis from 1990 and 2019 increased from 0.74 million to 1.58 million. Aim is to evaluate the importance of adult stem cell therapy as an alternative to total hip arthroplasty in severe hip osteoarthritis.

Patient, Materials and Methods: A case of a patient that had adult stem cell therapy on account of severe right hip osteoarthritis. Right hip severity was assessed using the Harris Hip Score (HHS) and Western Ontario and McMaster Universities Osteoarthritis Index (WOMAC) scale. Radiologic studies (X-ray and MRI) were done. Patient had a session of adult stem cell therapy (autologous mesenchymal cells) and was observed for 6 months, then had allogenic exosomes and plasma rich platelet therapy. At 10 months, patient had another session of ADSC Therapy and PRP Therapy and was observed with a follow up for 24 months.

Results: The WOMAC and HHS assessed on the (0,6,12 and 24 months) showed quality improvement from an initial score of 96/96 to a score of 0/96 and from 31% to 97% at 24 months respectively. Post procedure radiologic studies of the hip done at the same months showed marked progressive changes.

Conclusion: Adult stem cell therapy is a promising alternative method of treatment in people with severe hip osteoarthritis. Results showed a positive outcome according to all the grading systems used in this study and this patient was followed up for 24 months and is still being followed up which is proving its advantage in long term outcome.

Abbreviations

OA:	Osteoarthritis
BMAC:	Bone Marrow Aspirate Concentrate
BMSC:	Bone Marrow Stem Cell.
	Western Ontario and McMaster
WOMAC:	Universities Osteoarthritis Index Scale
HHS:	Harris Hip Score
PSIS:	Posterior Superior Iliac Spine
SVF:	Stromal Vascular Fraction
ADSCs:	Adipose Derived Stem/Stromal Cells
MSC:	Mesenchymal Stem Cell
SAE:	Severe Adverse Event
AE:	Adverse Event
PRP:	Platelet Rich Plasma

Keywords: ADSC; HHS; WOMAC; Hip Osteoarthritis; PRP

Introduction

Hip osteoarthritis causes gradual loss of range of motion and is most often symptomatic during weight-bearing activities. Pain may be felt in the inguinal area or greater trochanter or referred to the thigh and knee, and it is usually accompanied with stiffness of the affected joint. It is one of the leading

causes of chronic hip joint pain and disability worldwide affecting older age individuals: usually symptomatic in the 40s and 50s and is nearly universal by age 80 [1,2].

Radiologic definition is symptomatic osteoarthritis of the hip classified as Kellgren-Lawrence grade 2-4. Grade 2 symptomatic OA involves one defined osteophyte in hip and pain for at least 1 month out of the past 12 months. Grade 3-4 symptomatic OA includes osteophytes and joint space narrowing in hip, with grade 4 also including deformity, and pain for at least 1 month out of the past 12 months [3,4].

Patients are initially treated with a combination of physical therapy, activity modification, weight loss, non-steroidal anti-inflammatory, and/or intra-articular injections with the goal of symptom modification. When OA progresses to the end stages (stage 3-4) and non-operative care fails, total joint replacement can be an effective alternative [5].

Mesenchymal Stem Cells (MSCs) are said to have regenerative capacity and can be separated from a variety of tissue sources including adipose (fat) tissue and bone marrow [6-9]. These cells have multi-potential abilities to differentiate into bone, cartilage, muscle, and fat and can be expanded in culture.

Adipose Derived Stem Cells (ADSCs) and Bone Marrow Derived Stem Cells (BMSCs) are MSCs which have been collected from fat and bone marrow respectively. Easily accessible subcutaneous fat from the abdomen or the flanks can be collected *via* mini-liposuction and contains high amounts of ADSCs [10]. These cells produce different cytokines and growth factors that when expressed is thought to be part of a healing cascade and new blood vessel formation by stimulating a local inflammatory process and immunomodulatory/paracrine response which enables a signaling that causes the repair of damaged tissue [11,12]. MSCs (ADSC and BMSC) are anti-inflammatory and promote angiogenesis [13,14]. Their complex signaling process causes the signaling of other cells to the area to repair damaged tissue which promotes regeneration. MSC has the potential to fully heal damaged tissues and organs and this ability has made MSC a potential game changer in respect to treatment of various diseases and injuries. The

exploitation of stem cells' ability to promote a healing cascade is a novel progressive shift in medicine.

The Stromal Vascular Fraction (SVF) is the mixture of cells from adipose tissue collected *via* mini-lipoaspiration after the adipocytes (fat cells) have been depleted. The remaining cells include a large percentage of ADSCs. SVF contains a variety of regenerative cells and growth factors and can be offered as an out-patient surgical procedure, it represents a new therapeutic tool for many indications.

Friedenstein et al, in a series of seminal studies in the 1960s and 1970s, showed that the osteogenic potential of Bone Marrow (BM) cells was associated with a minor subpopulation of cells in the BM. These cells were distinguishable from most hematopoietic cells by their rapid adherence to tissue culture vessels and the fibroblast-like appearance of their progeny in culture, pointing to their origin from the stromal compartment of BM. While now known to be technically incorrect, the current colloquial term "mesenchymal stem cell" dates to 1991. A work by Darwin Prockop and others further defined the cells and their multi-lineage capability. The ability to grow and expand them efficiently and relatively easily and the wide variety of functions they have now been described to perform to the birth of an entire subfield of cell therapy. The marrow stromal cell field expanded very rapidly, and the potential use of these cells in therapy is being tested worldwide for many indications. The potential utility of the cells lies in their multifunctional properties: They modulate the immune system, enhance engraftment of hematopoietic stem cells, promote tissue healing, and contribute to structures such as bone, cartilage, and fat. In addition, as culture-expanded cells, they may provide critical trophic support for normal tissue maintenance and protection and recovery from tissue injury [15,16].

Adipose tissue is quickly becoming the preferred source for stem cells as compared to bone marrow due to the relative higher amounts of ADSCs/MSCs and lower amounts of pro-inflammatory leukocytes [17].

Exosomes are nano-sized membrane bound vesicles secreted by Mesenchymal Stem Cells that contains cytokines, growth factors, signaling lipids, mRNA, and miRNA.

These cells play a role in cell-to-cell communication and cell signaling, affecting the body's response to injury, disease, and inflammation.

Local injection of MSCs (ADSCs and BMSCs) may reduce inflammation and promote healing/normal tissue formation. SVF can be collected bedside after a simple adipose tissue collection making it a practical surgical procedure for physicians to provide to their patients. Some publications have demonstrated success of MSCs for specific conditions including neurodegenerative disc diseases, osteoarthritis, and multiple sclerosis [18]. The following is a case report of a woman with right hip osteoarthritis.

Methods

The following case report started on the 13/11/2020. Diagnosed with severe bilateral hip osteoarthritis (stage 4). Patient had a left total hip arthroplasty for left severe hip osteoarthritis one and a half year prior to presentation and wished to have a procedure with adult stem cell therapy on the right hip as she did not want another surgical procedure done. The patient provided written informed consent to undergo the experimental clinical procedure as well as consent to publication of outcomes, images, and data.

Right hip severity was assessed using the Harris Hip Score (HHS) and Western Ontario and McMaster Universities Osteoarthritis Index (WOMAC) scale. Radiologic studies (X-ray and MRI) were done.

The treatment was done in 3 sessions. The first session was a combination of MSCs {ADSCs (svf) and BMAC} plus PRP. The second session was a combination of allogenic exosomes plus PRP done at 6 months. The third session was a combination of Stromal Vascular Fraction (SVF) plus PRP done at 10 months.

- **First treatment session proceeded after consultation and all necessary requirements were carried out.**

The SVF was created using a standard tumescent liposuction solution. Tumescent was introduced into the subcutaneous fat tissue in the lower abdomen using an infiltration cannula to create local numbing. Adipose tissue was collected with a harvesting cannula. Using a commercially available collection kit and collagenase enzyme, the collected fat was processed to obtain the SVF for injection/transplantation - 2

ml SVF from the collected fat (1.96×10^9 total *viable* cells per ml tested with 100% viability from MoxiFlow) for intraarticular injection, and 3 ml of SVF from the collected fat (3.15×10^9 total *viable* cells per ml tested with 100% viability from MoxiFlow) for Intravenous transplantation.

The Platelet Rich Plasma concentrate required for injection was prepared at the Glory Wellness & Regenerative Centre in Lagos, Nigeria by venipuncture of the patient.

Venous blood drawn from the patient was centrifuged at room temperature in order to separate the plasma, the blood, the buffy coat and residual red blood cells (RBCs). Using a 10 ml syringe, approximately 7 ml of PRP was collected.

BMAC was obtained through an ultrasound guided bone marrow aspiration, the left PSIS was located and anesthetized. Using a trocar, bone marrow was aspirated using heparinized syringes. BMAC of 4.5 ml was processed. After local anesthesia, the total of 8 ml mixture of SVF (2 ml – 1.96×10^9 total viable cells per ml tested with 100% viability from MoxiFlow), BMAC (3 ml) and PRP (3 ml of the 7 ml PRP processed from the whole blood) was injected into the right hip joint.

- **The second treatment session was performed 6 months after the first session.**

At 6 months patient had a second treatment session for her right hip joint using 5 ml (50 Ross units) of allogenic exosomes and PRP. The PRP concentrate required for injection was prepared by venipuncture of the patient. Venous blood drawn from the patient was centrifuged at room temperature in order to separate the plasma, the blood, the buffy coat and residual Red Blood Cells (RBCs). Using a 10 ml syringe, approximately 10 ml of PRP was collected. The allogenic exosomes were mixed with 2 ml of the 10 ml of PRP. The mixture of 5 ml exosomes and 2 ml PRP was injected intraarticularly into the right hip joint. Also, 8 ml of PRP was injected into the periarticular area of the right hip joint Figure 1a and Figure 1b.

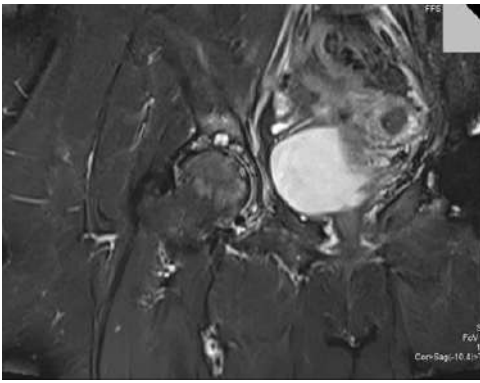


Figure 1a: MRI of the right hip joint(November 2020) - showed features of degenerative changes evidenced by

- 1) Reduction in the right hip joint space.
- 2) Multiple subchondral cysts seen in both sides of the joints.
- 3) Marrow edema is also appreciated in the acetabulum and femoral head.
- 4) Periarticular osteophytes are also seen.
- 5) Attenuated anterior Labrum.

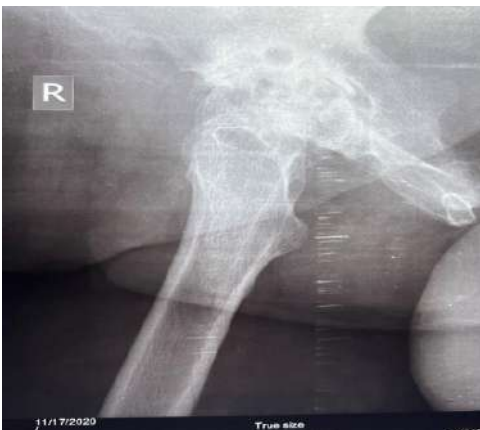

Figure 1b: X-ray of the right hip joint (November2020)- showed features of degenerative changes.

- 1) Pelvic asymmetry with a tilt to the right.
- 2) Subchondral sclerosis involving the right femoral head and acetabulum with subchondral cystic changes.
- 3) Marked osteophyte seen at the right acetabular boarder.
- 4) Marked narrowing of the right joint space.

• **The third treatment session was performed 10 months after the first session.**

At 10 months patient had the second session of SVF and third session of PRP. Using a commercially available collection kit and collagenase enzyme, the collected fat was processed to obtain the SVF for injection/transplantation - 2 ml SVF from the collected fat (8.99×10^8 total *viable* cells

per ml tested with 100% *viability* from MoxiFlow) for intraarticular injection, and 4 ml of SVF from the collected fat (6.87×10^9 total *viable* cells per ml tested with 100% *viability* from MoxiFlow) for Intravenous transplantation. For the third session of PRP, the PRP concentrate required for injection was prepared by venipuncture of the patient. Venous blood drawn from the patient was centrifuged at room temperature in order to separate the plasma, the blood, the buffy coat and residual Red Blood Cells (RBCs). Using a 10 ml syringe, approximately 7 ml of PRP was collected.

A mixture of SVF (2 ml) from the collected fat (8.99×10^8 total viable cells per ml tested with 100% *viability* from MoxiFlow) and PRP (2 ml from the obtained total 10 ml PRP) was injected intraarticularly into the right hip joint. The remaining PRP (8 ml) was injected into the periarticular area of the right hip joint.

The patient was monitored for any safety events including Adverse Events (AEs) and Severe Adverse Events (SAEs) before, during and after all the procedures. SAEs are defined as any fatal or life-threatening events leading to hospitalizations or requiring major medical interventions. Baseline parameters collected included blood work, radiographic imaging, vitals (blood pressure, pulse, temperature, respiratory rate). Radiographic imaging was done at 6 months, 12 months and 24-months post procedure (Figure 2-4).

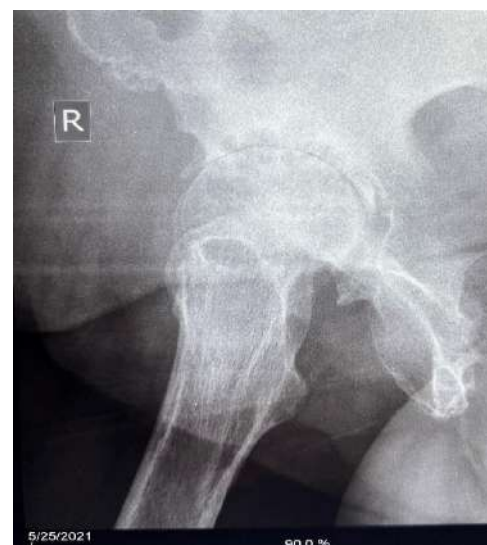

Figure 2a: X-ray of the right hip joint 6months post procedure (May 2021)- As shown in Fig. 2a.

- 1) Pelvic symmetry is preserved.

- 2) Marginal osteophyte is seen at the right acetabular margin.
- 3) Marked narrowing of the right hip joint space
- 4) Subchondral acetabular sclerosis.

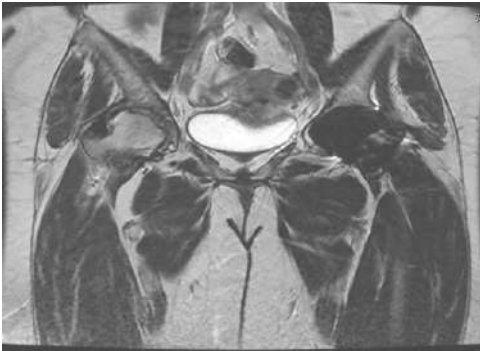

Figure 2b: MRI of the right hip joint 14 months post procedure (February 2022) - As Shown in Fig3a and 3b.

- 1) Moderate narrowing of the right hip joint space.
- 2) Associated subchondral cyst are seen.
- 3) Minimal right hip joint effusion seen.

THERE WAS A COMPARISON WITH THE 1ST MRI DONE IN 17/11/2020 AND THERE WAS NO DISEASE PROGRESSION NOTED.

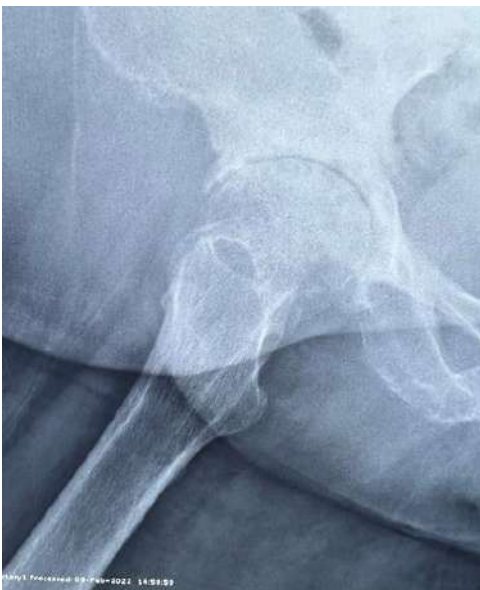

Figure 3a: X-ray of right hip joint 14 months post procedure (February 2022)

- 1) Sclerosis on the head of the right femur and acetabular rim.
- 2) There is an osteophyte seen on the lateral margin of the superior acetabular rim.
- 3) The obliteration of the right hip joint space.

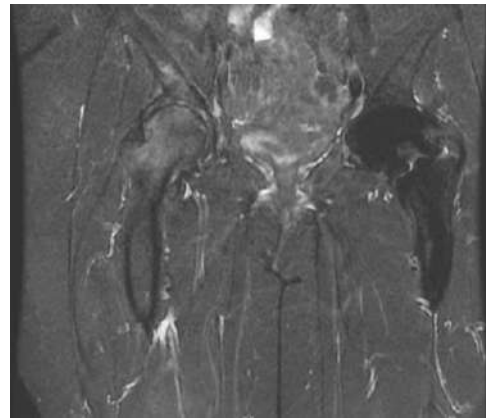


Figure 4a: MRI of the right hip joint at 24 months post procedure (November 2022).

- 1) Right joints appear normal in alignment.
- 2) No evidence of joint effusion
- 3) There is joint space reduction with altered signal intensity of the femoral head and neck with heterogenous hyperintensity.
- 4) Intensity of demonstrated bone is preserved.

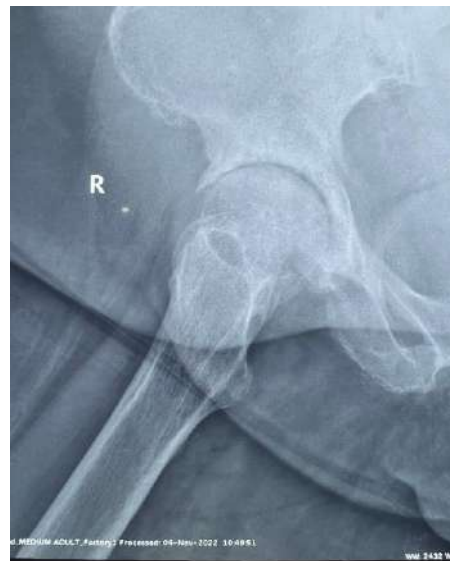

Figure 4b: X-ray of the right hip joint 24 months after the procedure (November 2022).

- 1) There is an osteophyte seen on the lateral border of the superior acetabular rim.
- 2) There is sclerosis of the acetabular rim and the articular margins of the femur.

Results

The entire procedure from the mini-lipoaspiration, the blood collection, and the SVF + BMAC + PRP injection was well tolerated during the initial treatment session with no reported adverse events, as well as the follow up treatment session at 6 months with PRP plus allogenic exosomes stem

cells, and another session of SVF plus PRP at 10 months. During the follow up period of 24 months, the patient did not report any AEs or SAEs. Normal activities were resumed in under a week and the patient reported back after 22 days post first treatment session with much improvement noted and reported a willingness to repeat therapy should it be necessary. During the follow up period, the patient reported improvements in aspects to pain and function of the hip as assessed by the WOMAC and HHS.

WOMAC assessment showed an improvement from a total score of 96 at initial presentation to 21 at 6 months, 2 at 12 months and 0 at 24 months. HHS assessment showed an improvement from a total score of 31% at initial presentation to 76% in 6 months, 85% in 12 months and 97% in 24 months.

Radiologic changes were progressive and noted.

At presentation and MRI and X-ray of the Right hip was done as shown in Figure 1a and 1b respectively.

Reports by the radiologist noted.

Discussion

Osteoarthritis is a chronic joint disease that has evidence based conservative treatment options like exercise, weight management, patient education and some medications for pain. Definitive therapy known for stage 4 is usually total hip replacement, which is a surgical procedure, which is where adult stem cell therapy has it advantage as it is minimally invasive, safe with no reported treatment related adverse effect.

Recent literature has revealed the anti-inflammatory and healing properties of stem cells. The use of autologous SVF and BMAC in conjunction with PRP could be a novel therapy. Future studies could help to establish appropriate clinical protocols including repeat dosing, quantity/volume of MSCs (BMAC and SVF) or concentration of PRP for specific indications. Also, future studies need to compare cases with and without intravenous transplantation of SVF to determine the extent of the role of systemic transplantation of autologous SVF in localized regeneration of the hip joints.

Proposed mechanisms of action in this patient could be a paracrine effect or engraftment of the injected cells. The

injection of the MSCs (ADSCs and BMSCs) most probably stimulated a reduction of inflammation followed by the formation of new, healthy tissue. Complete tissue remodeling because of a complex sequence of events stimulated by expression of growth factors, chemokines, and cytokines.

Direct injection of MSCs (SVF and BMAC) plus PRP in severe hip osteoarthritis can be effectively and safely completed in an outpatient setting according to this case study. The patient tolerated the procedure with no reported adverse events. Radiographic imaging depicted the stages of healing after a single injection of the cellular mixture. Anticipated outcomes for healing processes and detailed protocols could be determined with larger clinical studies.

Ethics Approval and Consent to Participate.

The patient provided written informed consent and agreed to participate in the study.

Consent for Publication

The patient provided written informed consent and agreed to have their data published.

Availability of Data and Materials

The datasets during and/or analysed during the current study are available from the corresponding author on request.

Authors' Contributions

DI and OO designed the protocol. DI was responsible for clinical procedures and follow up of patient. DI and OO wrote the manuscript. All authors contributed toward critically revising the paper and agree to be accountable for all aspects of the work. All authors read and approved the final manuscript.

References

1. Fu M, Zhou H, Li Y, Jin H, Liu X. Global, regional, and national burdens of hip osteoarthritis from 1990 to 2019: estimates from the 2019 Global Burden of Disease Study. *Arthritis Res Ther.* 2022;24:8.
2. Osteoarthritis. Merck Manual Professional Version.
3. <https://www.msdmanuals.com/professional/musculoskeletal-and-connective-tissue-disorders/joint-disorders/osteoarthritis-oa#v906141>.
4. Kellgren JH, Lawrence JS. Radiological assessment of osteo-arthritis. *Ann Rheum Dis.* 1957;16(4):494-502.

5. Taruc-Uy R, Lynch S. Diagnosis and treatment of osteoarthritis. Primary care. 2013;40(4):821-36.
6. Safiri S, Kolahi A, Smith E, Hill C, Bettampadi D, Mansournia M, et al. Global, regional and national burden of osteoarthritis 1990-2017: a systematic analysis of the Global Burden of Disease Study 2017. *Ann Rheum Dis.* 2020;79(6):819-28.
7. Comelia K, Ikudayisi D. Injection of Stromal Vascular Fraction Plus Platelet-Rich Plasma in a Non-Healing Decubitus Ulcer. *J Med Cases.* 2018;9(10):323-7.
8. Caplan AI. Mesenchymal stem cells: time to change the name! *Stem Cells Translational Medicine.* 2017;6(6):1445-51.
9. Hematti P, Keating A. Mesenchymal stromal cells in regenerative medicine: A Perspective. In: Hematti P, Keating A. editors. *Mesenchymal Stromal Cells. Biology and clinical applications.* New York: Humana Press; 2013:3-16.
10. Przybyt E, Harmsen MC. Mesenchymal stem cells: promising for myocardial regeneration? *Curr Stem Cell Res Ther.* 2013;8(4):270-7.
11. Minter D, Marra KG, Rubin JP. Adipose-derived mesenchymal stem cells: biology and potential applications. *Adv Biochem Eng Biotechnol.* 2013;129:59-71.
12. Gimble JM, Katz AJ, Bunnell BA. Adipose-Derived Stem Cells for Regenerative Medicine. *Circ Res.* 2007;100(9):1249-60.
13. Rehman J, Traktuev D, Li J, Merfeld-Clauss S, Temm CJ, Bovenkerk JE, et al. The Secretion of Angiogenic and Anti-Apoptotic Factors by Human Adipose Stromal Cells. *Circulation.* 2004;109;10: 1291-8.
14. Kobolak J, Dinnyes A, Memic A, Khademhosseini A, Mobasheri A, Mesenchymal Stem Cells: Identification, Phenotypic Characterization, Biological Properties and Potential for Regenerative Medicine through Biomaterial Micro-Engineering of Their Niche. *Methods.* 2016;99:62-8.
15. Caplan AI, Correa D. The MSC: An Injury Drugstore. *Cell Stem Cell.* 2011;9(1):11-15.
16. Viswanathan S, Keating A, Deans R, Hematti P, Prockop D, Stroncek DF, et al. Soliciting strategies for developing cell-based reference materials to advance mesenchymal stromal cell research and clinical translation. *Stem Cells Dev.* 2014;23(11): 1157-67.
17. Chahal J, Gómez-Aristizábal A, Shestopaloff K, Bhatt S, Chaboureau A, Fazio A, et al. Bone Marrow Mesenchymal Stromal Cell Treatment in Patients with Osteoarthritis Results in Overall Improvement in Pain and Symptoms and Reduces Synovial Inflammation. *Stem Cells Transl Med.* 2019;8(8):746-57.
18. Panfilov IA, de Jong R, Takashima S, Duckers HJ. Clinical study using adipose-derived mesenchymal-like stem cells in acute myocardial infarction and heart failure. *Methods Mol Biol.* 2013;1036:207-12.
19. Comella K, Parlo M, Daly R, Depasquale V, Edgerton E, Mallory P, et al. Safety analysis of autologous stem cell therapy in a variety of degenerative diseases and injuries using the stromal vascular fraction. *J Clin Med Res.* 2017;9(11):935-42.

[**SUBMIT MANUSCRIPT**](#)