

## Vascular Malformation of Cheek

**Garima Rawat\*** and **Gaurav Sharma**

Department of Pathology, Dharamshila Narayana Hospital, New Delhi, India

Received Date: June 15, 2023; Accepted Date: June 24, 2023; Published Date: June 29, 2023

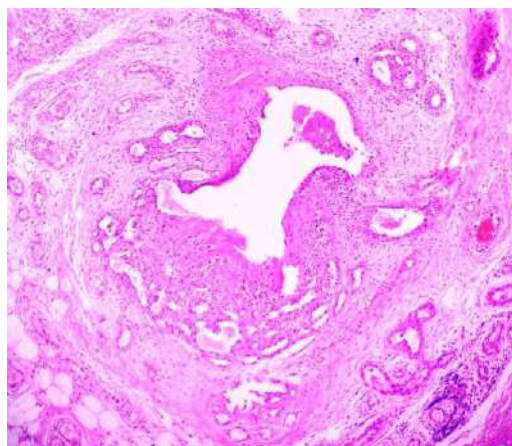
\***Corresponding author:** Garima Rawat, Department of Pathology, Dharamshila Narayana Superspeciality Hospital, New Delhi, India, Tel: +91-9873776634; E-mail: garima3103@gmail.com

**Citation:** Garima Rawat. Vascular Malformation of Cheek. *Clinical Surg.* 2023;2(1):1009.

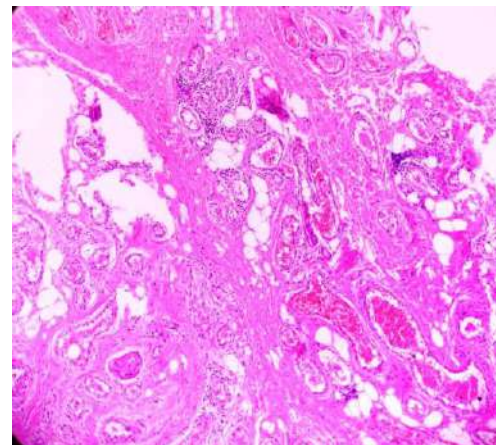
**Copyright © 2023 Garima Rawat.** This is an open access article published under the Creative Commons Attribution License, which permits unrestricted use, distribution, and reproduction in any medium, provided the original work is properly cited.

### Clinical Image

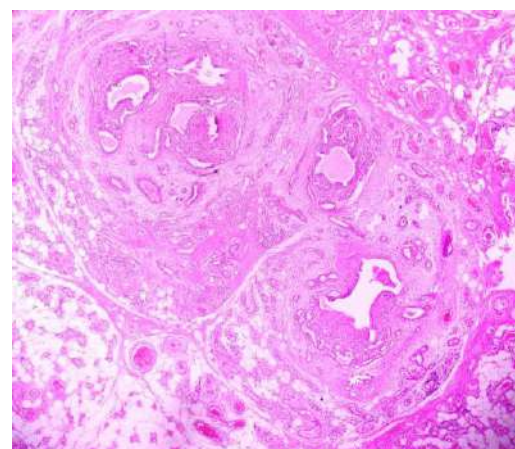
A 48-year-old male patient with a non-contributory medical history reported to a tertiary care hospital with the chief complaint of swelling on right side of face. The swelling was not associated with any pain and had gradually increased to the present status. Clinically a provisional diagnosis of dermoid cyst was made and the lesion excised in toto. The specimen was submitted for histopathological examination. The microscopic findings were suggestive of vascular malformation (Figure 1-3).



**Figure 1:** shows vascular lesion (HE 40 ×).



**Figure 2:** Photomicrograph shows variably sized vascular channels (HE 100 ×).



**Figure 3:** Photomicrograph shows surrounding buccal fat (HE 100 ×).